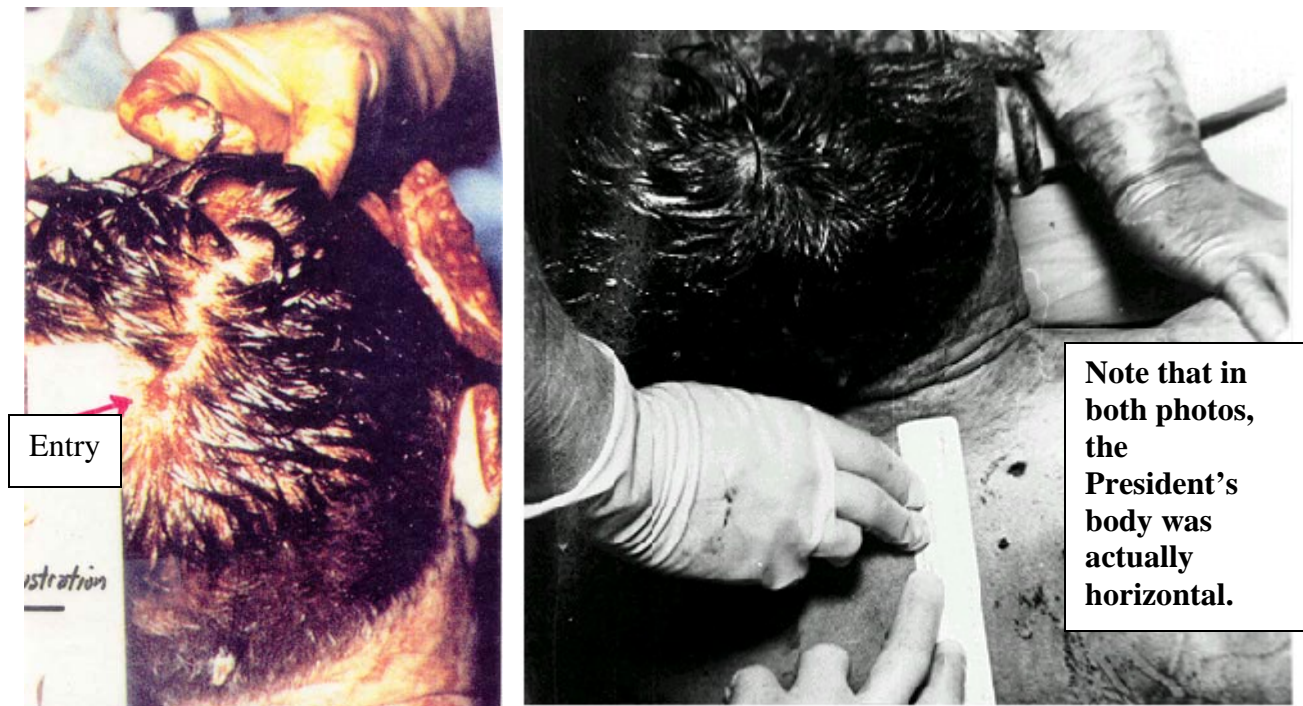

Were Key Autopsy Photographs Misinterpreted?

The series of autopsy photographs (two of them below right and left) showing the entry wound in the back of President Kennedy's head have been the subject of great controversy.



The controversy stems from the fact that, while the autopsy doctors insisted the entry wound to the back of the President's head was "slightly above" the External Occipital Protuberance (EOP), the aforementioned photographs show that the wound in the scalp appears to be over the posterior parietal ("cowlick") portion of his head.

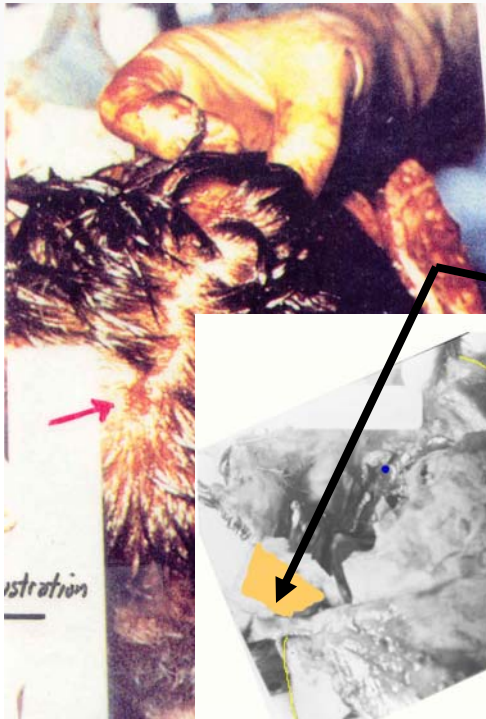
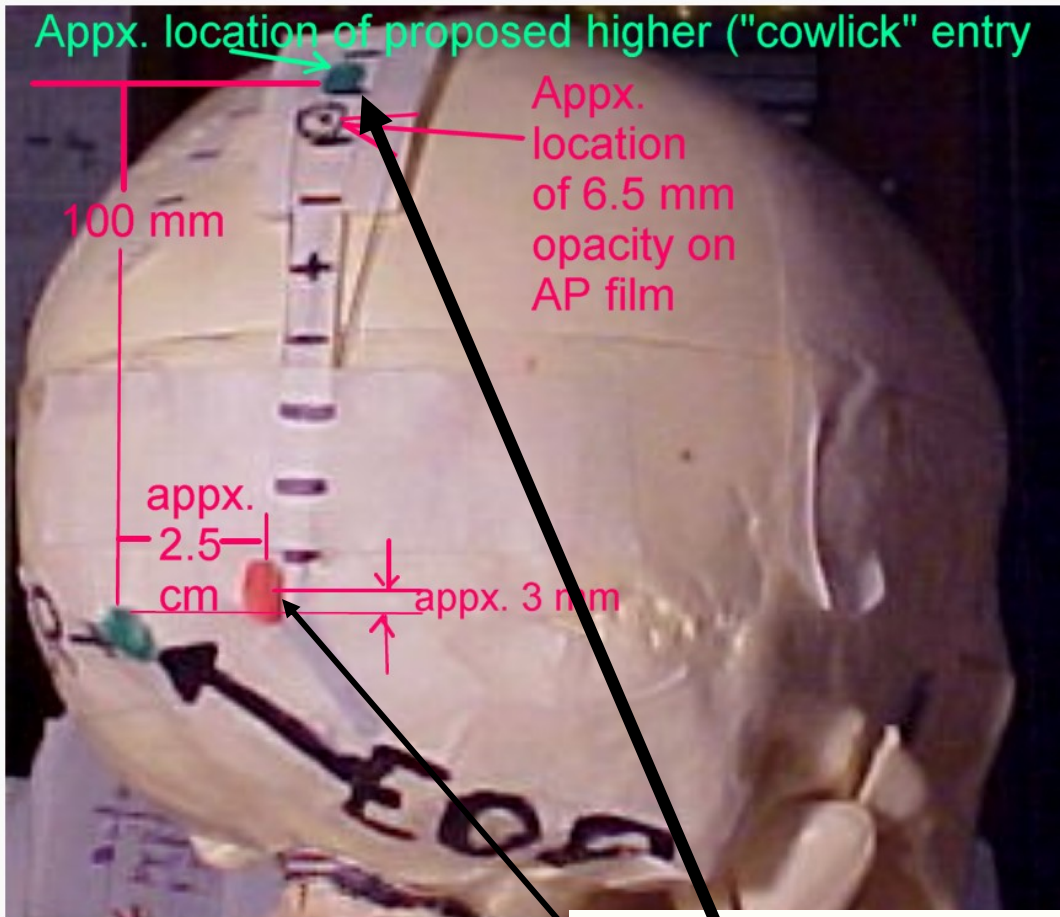
When questioned years after the fact about why the above photos seem to show the entry well above where they insisted it was in the skull (they reported it was "approximately 2.5 cm to the right and 'slightly above' the EOP"), the autopsists seemed to be confused and even denied that the entry wound shown in the scalp in the photos was indeed "the" entry wound.

Dr. Humes stated: "Dr. Boswell offered the interpretation that it might be an extension of a scalp wound. I don't share his opinion about that. I don't know what that is No. 1, I can assure you that as we reflected the scalp to get to this point there was no defect corresponding to this in the skull at any point. I don't know what that is. It could be clotted blood. I don't know what it is, but it certainly was not any wound of entrance." [7HSCA, p. 254]

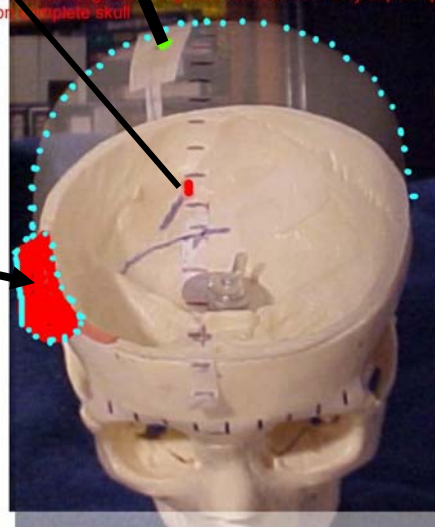
Dr. Humes' contention that the entry wound was near the EOP, as opposed to where the above photos seem to show it, does have significant support that includes these facts:



1. Dr. Joseph Davis, a member of the HSCA's Forensic Pathology Panel pointed out to his colleagues on the panel that a trail of opacities could be seen on the lateral x-ray extending from near the level of the EOP. Dr. Chad Zimmerman and Larry Sturdivan, who both examined the original x-rays and photos in 2006 and have concluded the entrance wound was near the EOP, confirmed the presence of these opacities. Both also explained that the opacities undoubtedly represent the pieces of bone beveled out from the inner tables of skull around the entry wound.

- 2. Other witnesses who saw the entry wound to JFK's head agreed the autopsists' recollections were correct regarding its location. For example, Chester Boyers, in charge of the Pathology Laboratory when JFK's autopsy was performed, stated to the HSCA that he recalled that the entrance wound was in the rear of the head to the right of the EOP. [HSCA Record Number Agency File Number 01314, dated 4/25/78] Dr. Robert Grossman, a neurosurgeon who helped try to save the President's life in Emergency Room No. 1, at Parkland Hospital, in 1981, told Ben Bradlee, a reporter for the Boston Globe, that he saw an entrance wound in the occiput. On 2/21/97, he told interviewers for the Assassination Records Review Board (ARRB) basically the same thing. [ARRB, MD-185]**
- 3. The brain damage reported by the autopsists seems quite consistent with a bullet entering near the EOP, with the major fragments from that bullet exiting just forward of the coronal suture, roughly two inches right of midline. They reported that there was a longitudinal laceration that began, 2.5 cm to the right of midline at the tip of the occipital lobe and extended through the tip of the frontal lobe. Other brain damage consistent with their entry wound included, 1) a laceration of the Corpus Callosum from its genu to its tail, 2) exposure, due to the aforementioned longitudinal laceration, of the Thalamus, and 3) the same laceration extending through the floor of the Third Ventricle behind the Optic Chiasm and Mammillary Bodies.**
- 4. The bullet's (largest fragments) path through JFK's head from near the EOP to the agreed exit area in the skull forward of the coronal suture seems to point towards the general direction of the windshield where it was reported two large bullet fragments hit the glass and chrome trip.**
- 5. The replications of the photograph of the skull (with the brain removed), showing the entry in the inside of back of the skull, by four assassination researchers/authors (performed independently of each other) constitute strong evidence that the entrance wound was near the EOP. Please refer to the following demonstration in which I superimpose (at 50% opacity) a photo of a full size, male model skull (with the near EOP and proposed higher "cowlick" marked on it) onto the photo of the skull with the brain removed that also shows the entry on the inside of the rear skull. Note that the graphics demonstrating the replication of this photograph performed by Larry Sturdivan can be seen in his book, *The JFK Myths* on pages 202 and 203. The first graphic shows the back of the model. The next shows the model realigned facing front and orientated as closely as possible to the way JFK's skull was orientated when the photo of his head was taken with his brain removed.**



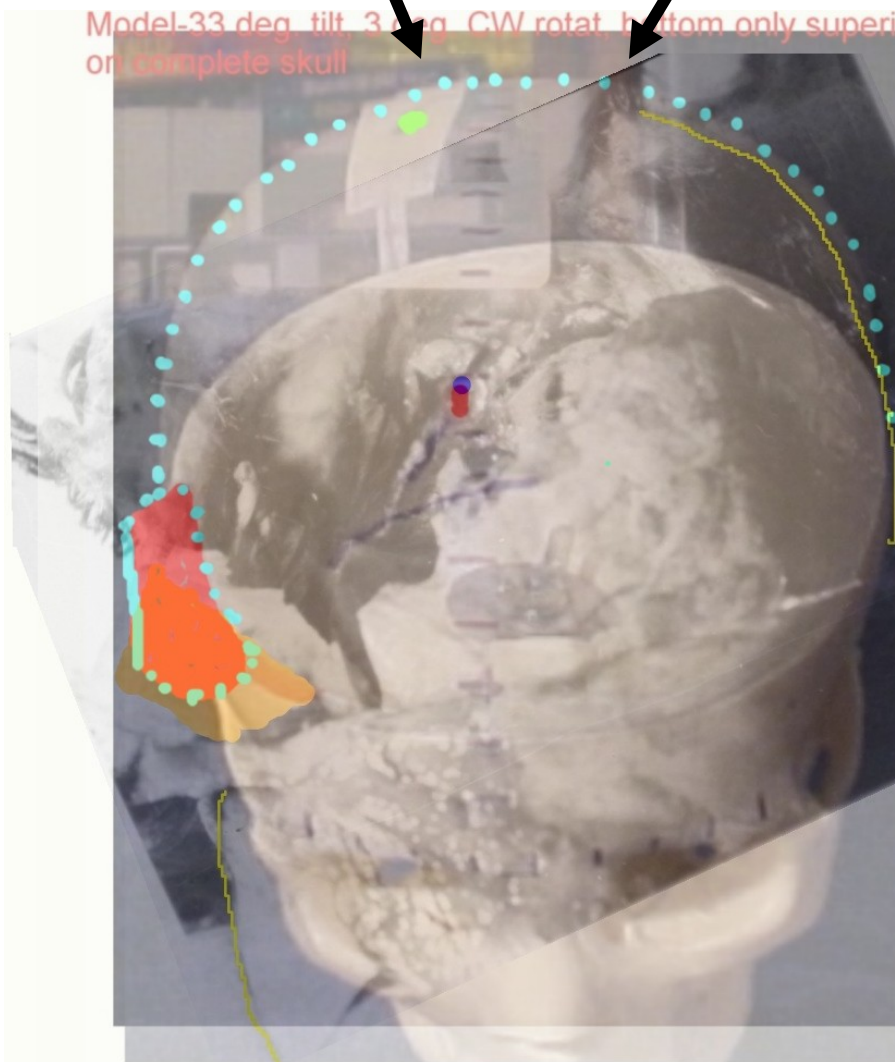
Model-33 deg_tilt_deg_CW rotat_bottom only superimposed on complete skull





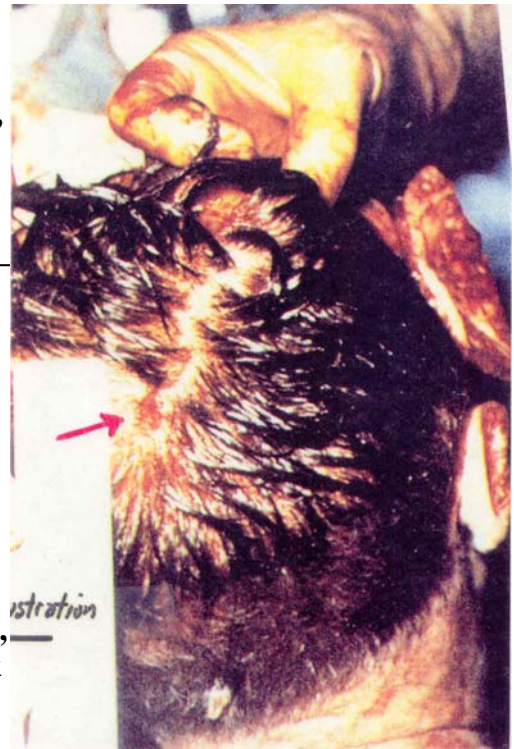The photo of the model (above right) has been superimposed onto the autopsy photo of the skull with the brain removed. Note that:

1. The flap on the model (red) reasonably corresponds to the flap on the autopsy photo (orange).
2. The blue dots on the model, indicating the top left rear skull profile reasonably correspond with the yellow dots in the autopsy photo highlighting the top left rear of JFK's skull profile.
3. The red dot, indicating the near EOP entry wound on the model reasonably corresponds with the blue dot on the autopsy photo which highlights the entry shown in the photo in the inside of the rear of JFK's skull.
4. The green dot on the model corresponds approximately with a point in the autopsy photo that is above the ruler where the fingers of the autopsists holding that ruler are.

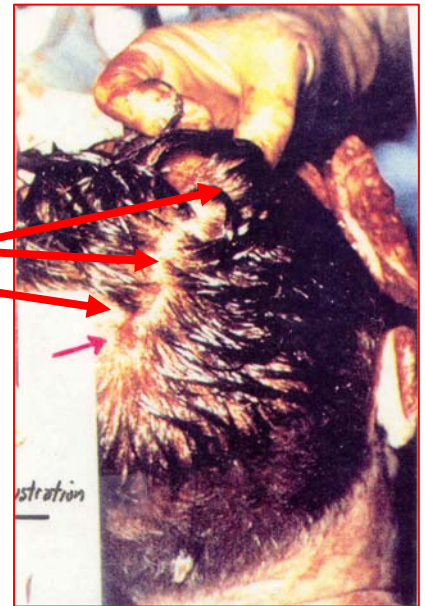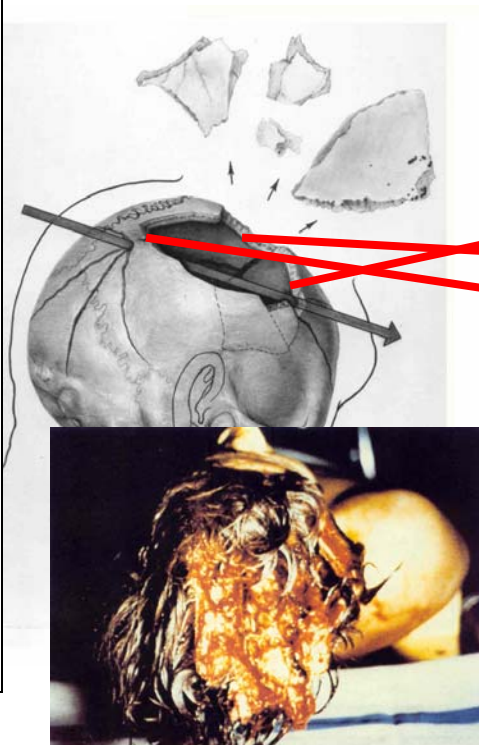


So, the question is begged, “If the evidence shows that the entry in the skull was near the level of the EOP, then what can the explanation be for why the autopsy photo of the back of the President’s head seem to show that the entry is in the “cowlick” area of the scalp (in other

words, why is it about six to seven inches above the hairline—a point in the scalp corresponding with the EOP area of the skull would typically be about three to four inches above the hairline)? I have spent an enormous amount of time, perhaps more than anyone (obsessed? Yes, I'd say so) during the past nine years looking at the photo below trying to answer the above question. Only recently, something Dr. Humes said, rather innocuously, in his deposition to the ARRB led to me considering an explanation for the conflict, besides the autopsists' explanation that the defect shown in the photo, which is clearly the entry wound, IS NOT THE ENTRY, or the theory advanced by some others that the scalp was "slid" upwards. Indeed, Humes said they assisted the morticians until the body was removed from the morgue—approximately at 5:00 AM, on 11/23/63.....and that they "UNDERMINED" the scalp" (so they could stretch it [the scalp] in order to close the large area in the scalp where it was missing or severely macerated due to the corresponding bone being blasted out of his head into Dealey Plaza and/or the limo). That area of skull that was blasted out extended from the posterior parietal forward to a few cm past the coronal suture on the right side of his head. Please refer to the drawing below to understand where the area was that was blasted out....it is not perfect, but for this discussion, it is close enough. Now, please look at the area of his head in the autopsy photo to the right that corresponds to where the skull was blasted out. Note that, aside from the apparent laceration that has been evidently sutured closed, the scalp appears to be undamaged.



So, the \$64,000 question is, "Why does the scalp in that area appear relatively undamaged when the autopsy report stated that the scalp in that area was "missing". Note that Humes didn't say it was "completely" missing...he simply said missing, so I'll assume that much of it was missing and some was severely macerated. Note that Clint Hill testified that he saw a piece of the President's skull in the limo with hair on it.



I strongly believe that they "undermined" the scalp (which maximized the amount they could stretch it) and stretched it so that:

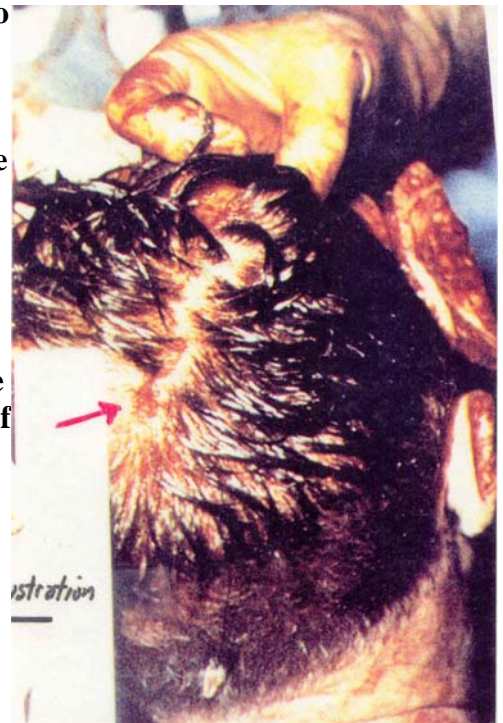1. The entry wound was (after the scalp was stretched) no longer about 3 to 4 inches above the hairline—it was 5 to 6 inches above it.
2. The area of relatively undamaged occipital scalp (aside from the aforementioned laceration that was closed) covered most of the area where the bone had been blasted out and the scalp missing and/or macerated.

Please note what one hair restoration manual says about “undermining”. “By separating the scalp from the underlying muscles and supporting tissues in a process called ‘undermining’ more hair bearing scalp can ultimately be pulled forward into the balding area”. It’s important to also note that on the body of a deceased subject, the scalp could be stretched significantly more (for obvious reasons) than it could on the head of a living person.

I checked with two morticians and both said that the rear scalp of the President could have been stretched, in their opinion, three inches and perhaps even a little more. They also said that the “sparser” hair density in the area from about the EOP down to the hairline is evidence that the scalp was stretched in that area.

It’s important to note also, that the morticians also testified the Scalp was stretched and sutured closed in preparation for an open-casket funeral.

Summing up, it’s unfortunate that the photos, like the one to the right, weren’t “time stamped” and the situation prior to their taking accurately recorded. Had that been done, I believe there would have been no controversy regarding the location of the entry wound. Moreover, the record would have shown that, as far as determining where the entry was in the *skull*, these photos showing where the entry was in a *scalp* (that had been extensively stretched and then closed in preparation for an “open-casket” funeral*) were not relevant. The bottom line is that the photos showing the entry in the *skull*** should have been the primary evidence (ONLY AFTER THE AUTOPSY FINDINGS) for determining where the entry was” in the skull”.



*The plans for an open-casket funeral were later aborted.

**The experts who examined the medical evidence for the Clark Panel were the first to report that the autopsists’ “near-EOP” entry wound location for the fatal bullet was grossly incorrect. They concluded, rather, based largely on the above-right photograph, that the fatal bullet entered approximately 100 mm above the EOP in the posterior parietal [“cowlick”] part of the President’s head. These same experts went on to say that the contrast was poor in the photo of the entry wound in the skull, making it unusable.

John Canal

Author of *Silencing the Lone Assassin* (Paragon House, 2000)